smile nova



LOVE &SMILE

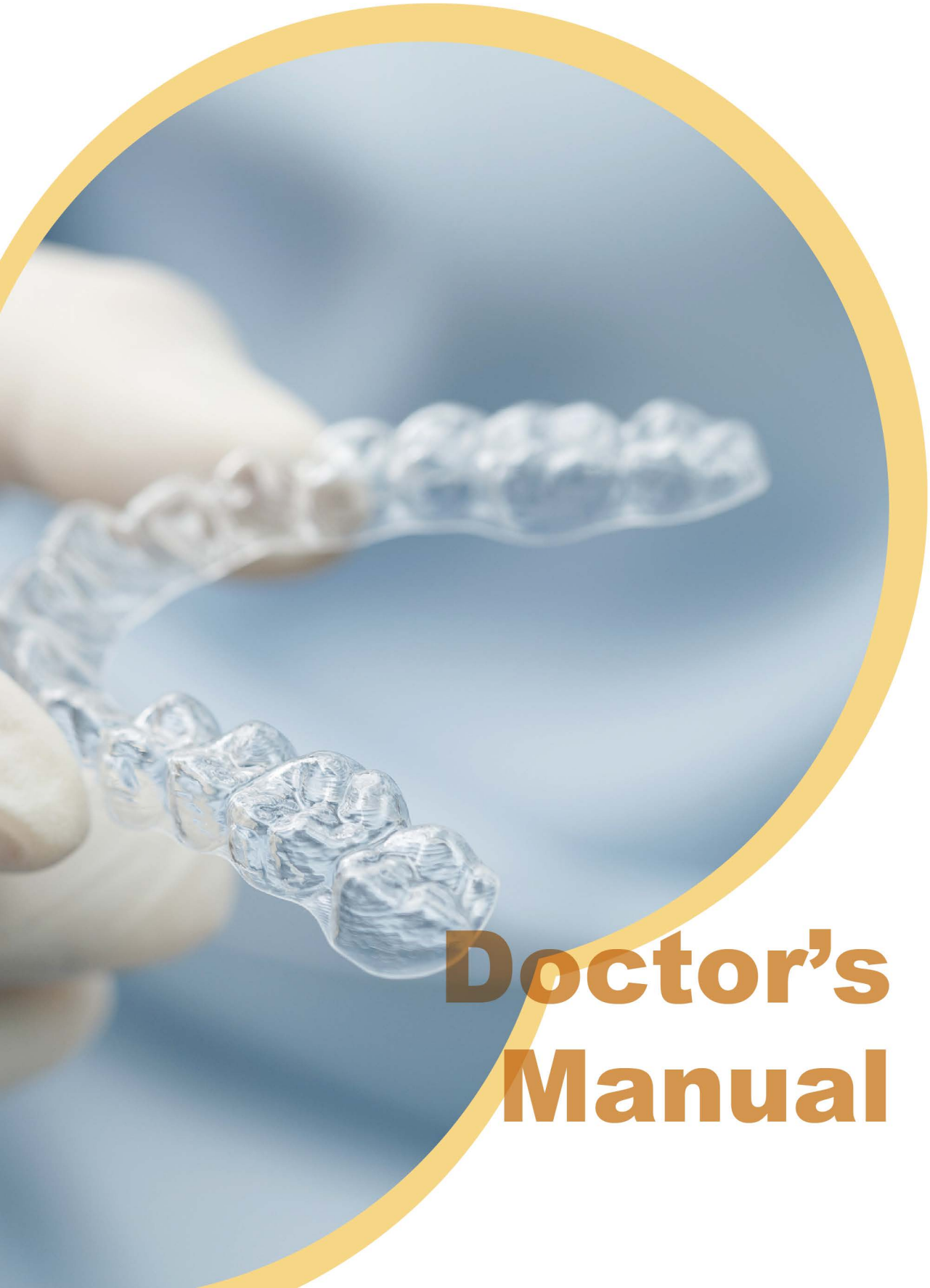

Doctor's Manual

Contents

Essential clinical data ---------- Page 1

Indication selection ---------- Page 4

Clinical operation ---------- Page 5

Potential issues ---------- Page 12



Essential Clinical Data

Photographs

PART I

Intra-oral photographs

Center smile, left bite, right bite, upper arch and lower arch.

* Tools needed: camera (mobile phone alternatively), intra-oral mirror, cheek retractor, lateral retractor and lip retractor.

Guide for intra-oral photographs



1) Center smile

Align the midline of the cheek retractor handles and the occlusal plane, pull cheek retractors apart symmetrically left and right, and then pull them forward, so that they are equally distributed on the four corners of the picture.

2) Left/right bite

Ask the patient to lie down and turn his/her head as much as possible. Photograph vertically between the canine and the first premolar, and make sure the other molars are occluded and exposed.

3) Upper/lower arch

The intra-oral mirror shall have no contact with the last molar; the midline should be located in the center of the mirror; there should be some gap between the mirror and the left and right molars; the jaw plane of the first molar should coincide with the focus.

PART II

Patient's new photos

Full face with lips relaxed, full face smiling and profile facing left/right.

Guide for patient's new photos





1) Photograph in white or light background.

2) Keep a distance from the background to reduce shadows.

3) Teeth in occlusion.

X-rays

A panoramic (around the head) and a lateral cephalometric (side) X-ray.

Guide for X-rays




1) The panoramic (around the head) X-ray should have a clear range and cover the condylar/condyloid process on both sides.

2) The lateral cephalometric X-ray requires that the right margin should be 2cm beyond the tip of the nose, the upper margin 3cm beyond the forehead point, and the lower margin 3cm beyond the soft tissue chin bottom.

Impression and bite registration

1) Use intra-oral scanner to directly take impression and bite registration records and generate data files in STL, OBJ, PLY, DCM or 3OXZ formats.

2) Use model scanner to generate digitized data files of impression and bite registration records taken with PVS material.

* Tools needed: polyvinyl siloxane (PVS) impression material, impression tray, bite tray, latex-free gloves, intra-oral scanner, model scanner, etc.



Indication Selection

Theoretically, most orthodontic patients can be treated with SmileyNova Pro clear aligners. However, if it is your first time conducting clear aligner treatment, we recommend that you choose a relatively simple case.

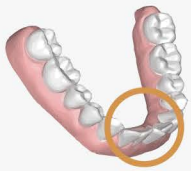

Crowded Teeth

Mild or moderate crowding



Spaced Teeth

The gap between anterior teeth is less than 5mm



Extraction

Relieving crowding by extraction of lower incisors



Extrusion

Teeth extrude less than 2.5mm



Rotated teeth

Teeth rotate less than 40 degrees

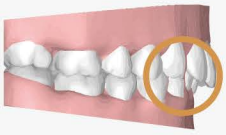

Deep overbite

Class I or II overbite

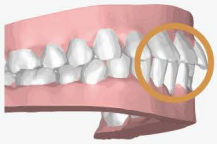

Overjet

Horizontal overlap between upper and lower teeth is more than 3mm, but less than 4mm



Underbite

Dental anterior underbite



Midline Misalignment/-Shift

Adjustment of midline is less than 3mm

* Sufficient clinical crown height is the basis of adequate orthodontic force, so the orthodontic effect of cases with short crown height will be affected.

* The above is just displays of individual indications. Normally, a patient' s case is composed of more than one indication.

* Please assess according to the actual situation of the patients. Complex correction requires longer treatment time.

Clinical Operation

PART I

Clinical operation before wearing--IPR

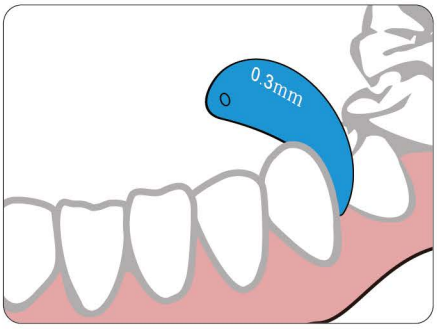

IPR gauge

Place the IPR gauge into the diastema, parallel to the adjacent surface of the tooth and reach the neck of the tooth. There should be some slight resistance, but it can be taken out smoothly. The patient's teeth should have no obvious squeezing feeling.

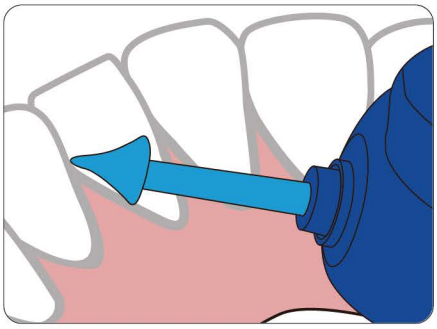

Trimming drill

The use of tooth trimming drill can trim the shape of teeth and ensure better adjacency.

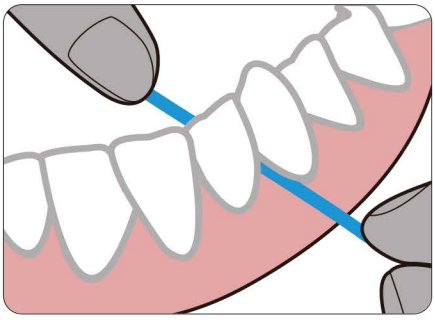

Floss

Dental floss can be used to measure the adjacency between two teeth.

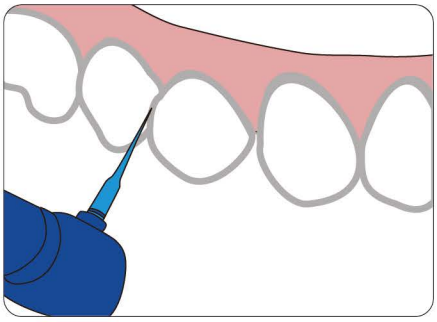

High speed dental bur

The minimum amount of enamel removal is 0.4mm. Be careful not to damage the tooth morphology.

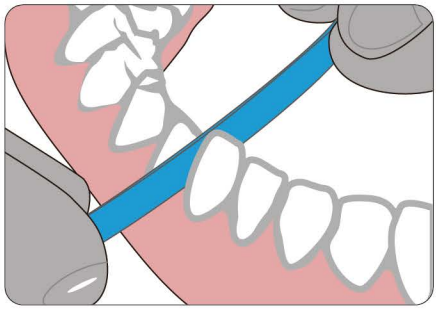

Abrasive strip

It is mostly used to open the adjacency relation, or a small gap (less than 0.2mm). Pull the strip back and forth to gradually achieve the desired effect, and pay attention to the protection of soft tissues such as lips.



* Please perform IPR by repeating the operation with little enamel removal amount every time to avoid excessive enamel removal.

* For the amount of enamel removal greater than 0.4mm, please choose high-speed dental bur, and for less than 0.4mm, please choose abrasive disc or strip.

* For rotated teeth and tipping teeth, the implementation of enamel removal requires rich clinical experience. First, mark the long axis of the tooth, and mark the safe range of enamel removal parallel to the long axis of the tooth. The split ring can be used to create a temporary gap to facilitate the use of tools.

* Please be sure to polish and apply fluorine on the adjacent surface after IPR to prevent caries.

* Use the IPR gauge correctly.

PART II

Clinical operation before wearing --placement of attachments

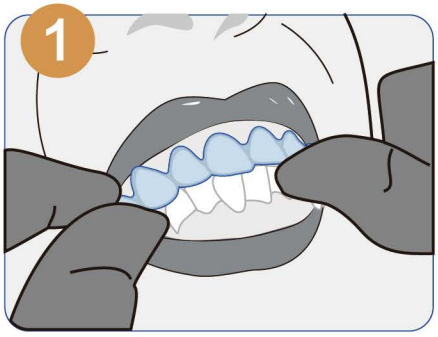

Try-on template

Rinse the attachment template with clean water and try it on in the patient's mouth to ensure that the attachment template fits closely with the teeth.

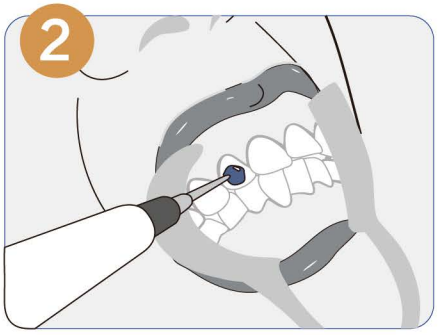

Tooth surface treatment

Apply adhesive only to areas where attachments will be placed. According to the instructions of the adhesive, some adhesives need to etch the tooth surface before use.

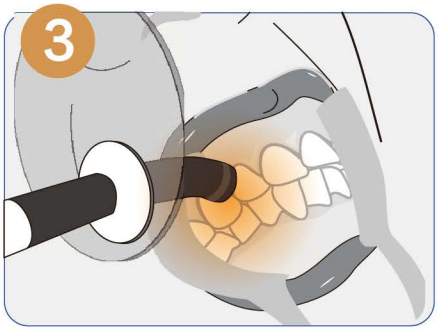

Light curing

According to the adhesive instructions, use a light curing lamp to irradiate the tooth surface.

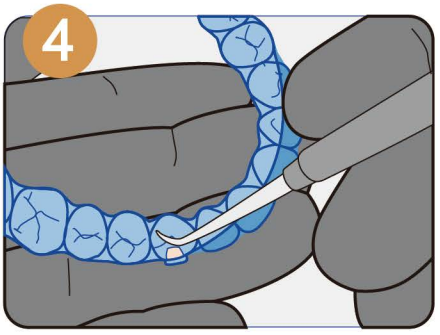

Fill in composite material

Choose resin materials with appropriate colors. Take an appropriate amount of resin material to fill the attachments area on the template and better overfill a tiny layer of material.

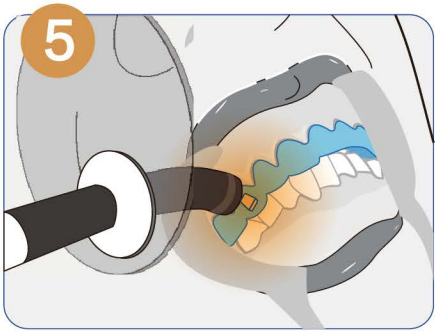

Curing attachments

Fully seat loaded attachment template onto the teeth. Apply gentle pressure around each attachment to ensure full adaptation. Use a light curing lamp to cure the attachments.

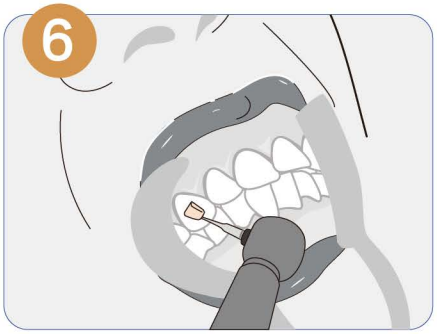

Finishing and polishing attachments

Gently remove the attachment template, trim the shape of the template with a dental bur, and polish it with a polishing bur.

* If the tooth surface needs etching before applying the adhesive, please rinse it after etching. Please keep the attachment template after use in case the attachment falls off during the treatment. Separate tooth position can be cut from the template to place some attachments on special positions. If the attachment is missing or cannot be used, please contact us in time.

PART III

Guide for return visits during the treatment

Inquiry

1) Whether there is discomfort in teeth, joints or muscles (time, characteristics and which body part).

2) Wearing method, wearing time and aligner seaters' using condition.

Visual examination

1) With aligners put on: whether the aligners fit, whether they wrap well or whether there are air bubbles.

2) With aligners taken off: oral hygiene, attachments status, whether the root shape of alveolar bone has changed, and whether there are abnormal reactions caused by bad habits.

Palpation

1) Whether the anterior teeth are in premature contacts (whether the root is loose, etc.).

2) Press the bubble position to check whether it is dislocated (dislocation degree).

3) Palpate whether the roots are uncomfortable (analyze whether there is cracking and perforation or any tendency of those).

Compare

Whether the actual tooth movement is consistent with the 3D animation.

Inspection

1) Adjacency: check whether the space between teeth is sufficient with dental floss.

2) Occlusion: whether there are premature contacts, interference or abnormal occlusion.

3) When there is a problem with the root shape, CBCT can be taken for auxiliary examination.

4) Periodontal problems: when there are periodontal problems, you can take a panoramic X-ray for auxiliary examination.

Adjustment

1) Adjacency problem: is it necessary to do teeth stripping or perform IPR as planned?

2) In case of derailment or possible derailment, consider intervention: such as whether traction is needed, whether cutting and bonding should be done for performing traction, etc.

3) Periodontal problems: if there are severe problems, consider whether to suspend orthodontic treatment.

Psychological counseling

1) Let the patient understand the purpose of all clinical operations.

2) Enhance patients' trust through communication.

3) Establish a good communication relationship for making it easier to identify problems.



PART IV

Treatment completion--retention and refinement

Completion

After wearing the last step of aligners, if the teeth movement and occlusion meet the treatment plan, the orthodontic treatment will be considered completed.

The clinician can send the confirmation data of the case to us, and we will send out retainers for the case accordingly.

Same with the process before the treatment, it is required to send 5 intra-oral photographs, 3 patient' s new photos, 2 X-rays and digitized data of impression and bite registration which are taken after the treatment is completed.

Refinement

After wearing the last step of aligners, if the teeth movement and occlusion outcomes have some obvious gap with the treatment plan, the clinician should get current data of the patient and contact us to check whether the refinement is needed in time. The essential clinical data is the same with the process before the treatment. It is required to send 5 Intra-oral photographs, 3 patient' s new photos, 2 X-rays and digital data of impression and bite registration taken at the final check-up.

If it is confirmed for refinement, we will send out the refinement aligners ASAP. Please note that refinement treatment is only provided within 5 years since the treatment starts.



Potential Issues

Loss of aligners

If the aligner that the patient is wearing is lost, please ask the patient to wear the last step of aligners at first. At the same time, please re-order the current step of aligners from SmileyNova.

Fracture of aligners

In case of fracture of the aligners, please follow the same process as that of losing aligners.

Please make the note as detailed as possible in order for SmileyNova to promptly check the cause of the fracture. If possible, please record the photos of the broken aligners.

Attachment falling off

If any of the patient's attachments falls off during wearing, please use either of the previous aligners or the ones that patient is wearing as a template to re-place attachments.

Non-fit of aligners

If there' s a distance between the cutting ends of the anterior teeth before and after wearing, the aligner is considered as non-fit.

Generally, the causes for non-fit could possibly be: enamel removal amount is not enough, the patient does not wear aligners for enough time as required, or the multi-step aligners lag behind.

Solution:

If the distance＜1mm, ask the patient to wear the last step of aligners and replace them 10 days later.

If the distance＞1mm, please carefully check the reason, take a picture of the patient wearing it, and contact Clickalign to make refinement order immediately.



Fracture of the aligner



To judge whether the aligner fits or not

smileynova

SmileyNova

SmileyNova

SmileyNova

SmileyNova

Vonggo (Shenzhen) MedTech Co.,Ltd.
info@smileynova.com